特別企画3

「道具に親しむ：頭蓋内ステント戦国時代／何を選ぶか」

症例提示2

順天堂大学医学部　寺西功輔

第19回NPO法人　日本脳神経血管内治療学会関東地方会学術集会　2021.2.20

症例 ② 68 y.o. M

患者背景

現病歴：眼瞼ミオクローヌスの精査で偶然指摘された

無症候未破裂IC-Pcom瘤

既往歴：高血圧、腰部脊柱管狭窄症術後

家族歴：SAHなし

嗜好　：機会飲酒、喫煙歴あり

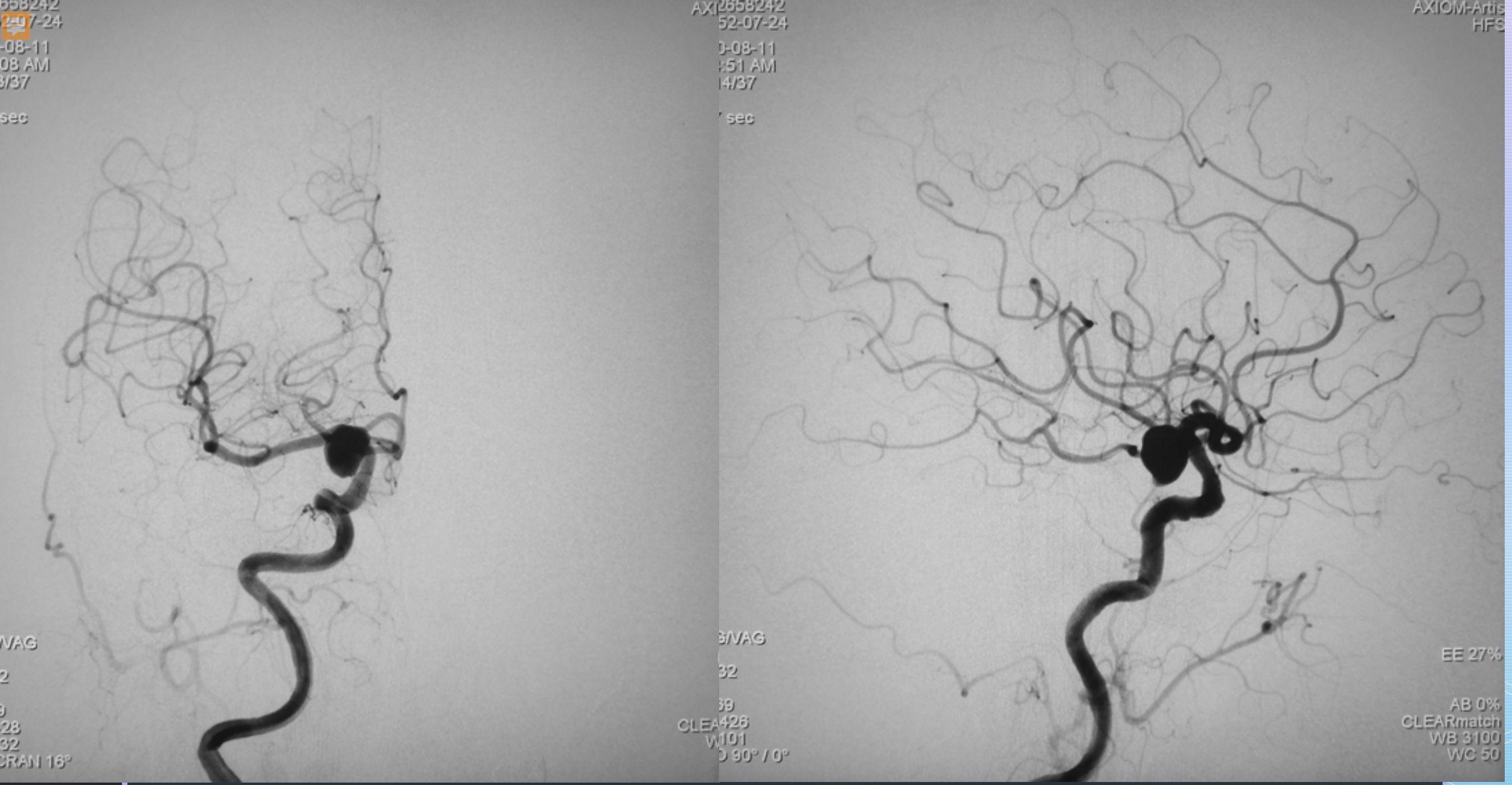

rt.ICAG

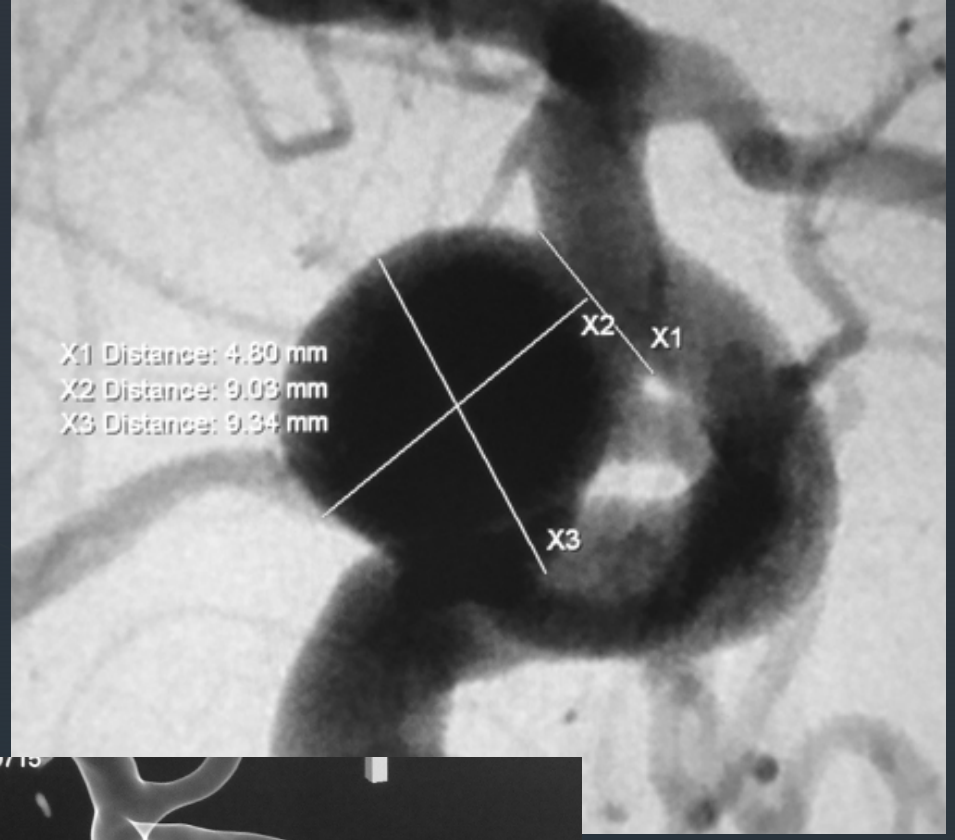

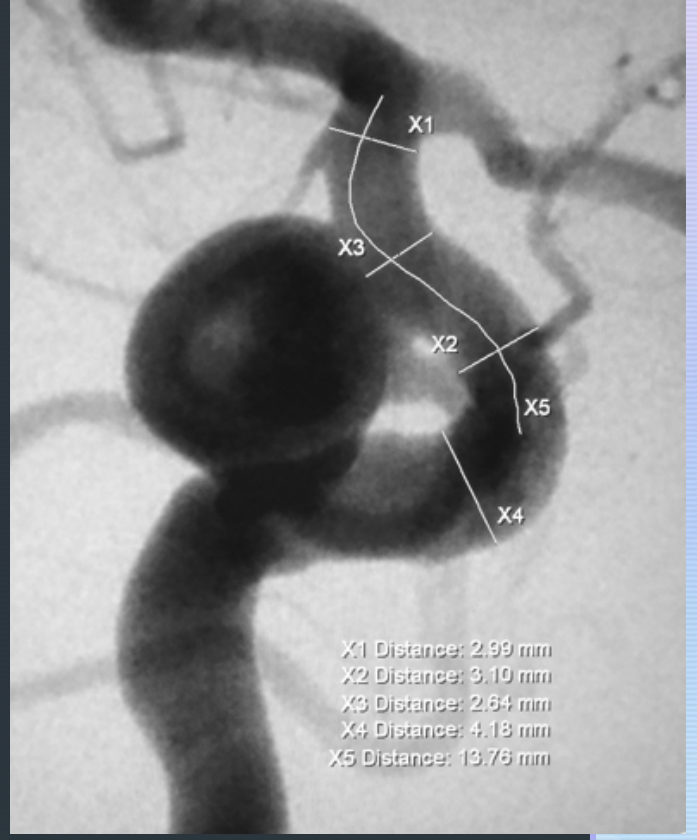

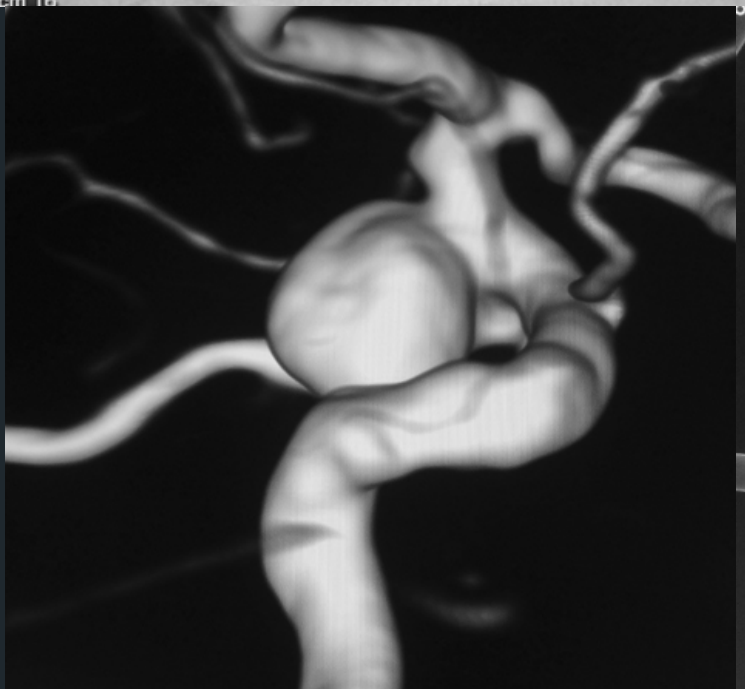

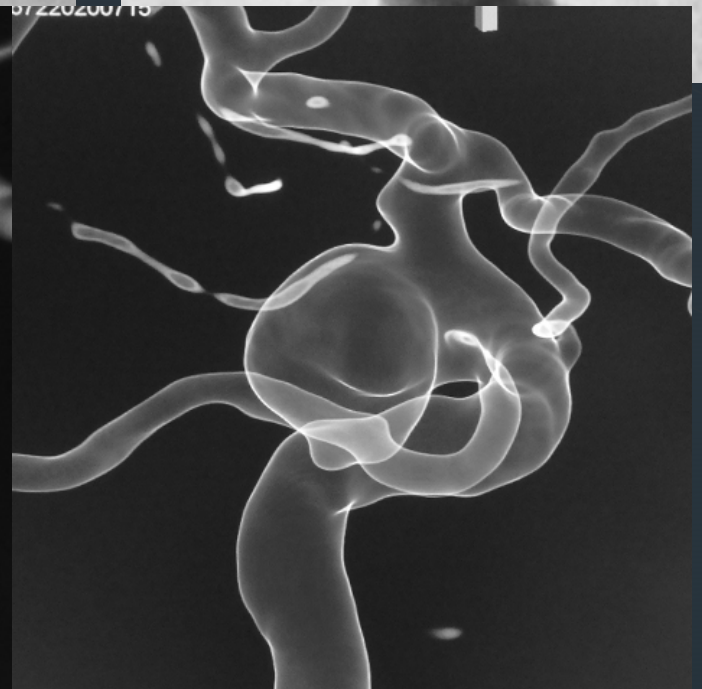

動脈瘤径
9.3x9.0x neck 4.8mm

IC径
3.1 ～2 .6mm

lt.VAG (Alcock test)

症例③　68 y.o. M

患者背景

現病歴：2020.4.23頭痛発症のくも膜下出血(Hunt&Hess G1, WFNS G1) で偶然指摘された破裂IC-Pcom瘤治療後半年の再発症例。

既往歴：高血圧

家族歴：SAHなし

嗜好　：機会飲酒、喫煙歴なし

発症時 rt.ICAG

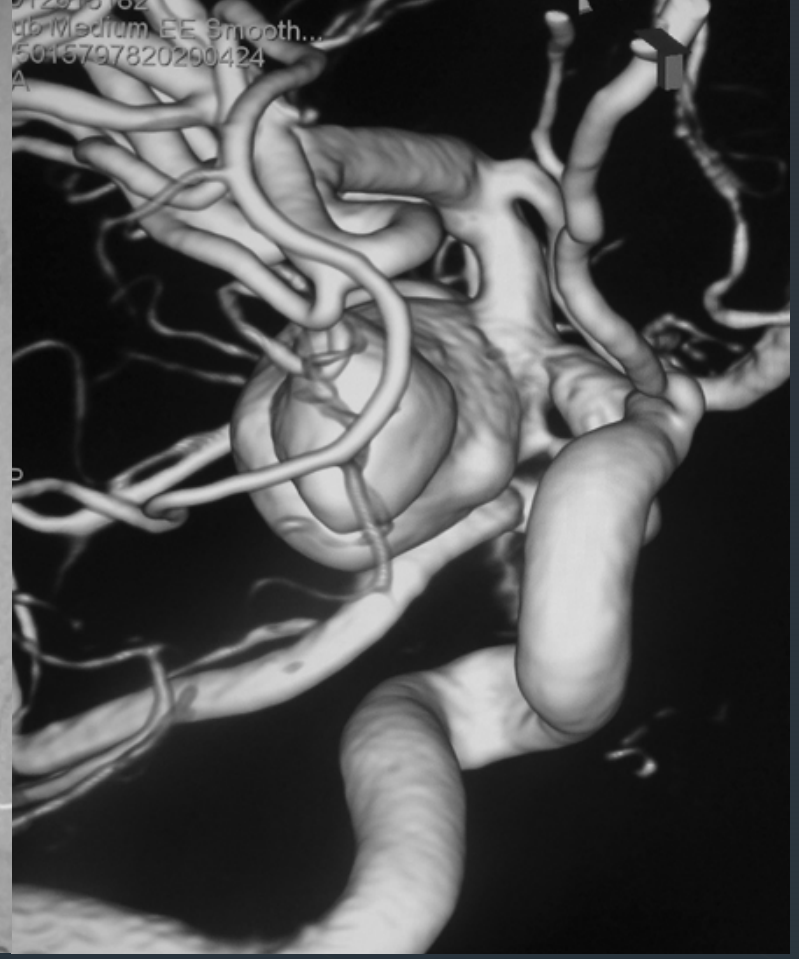

動脈瘤径
15.1 x 9.6x neck 4.5mm

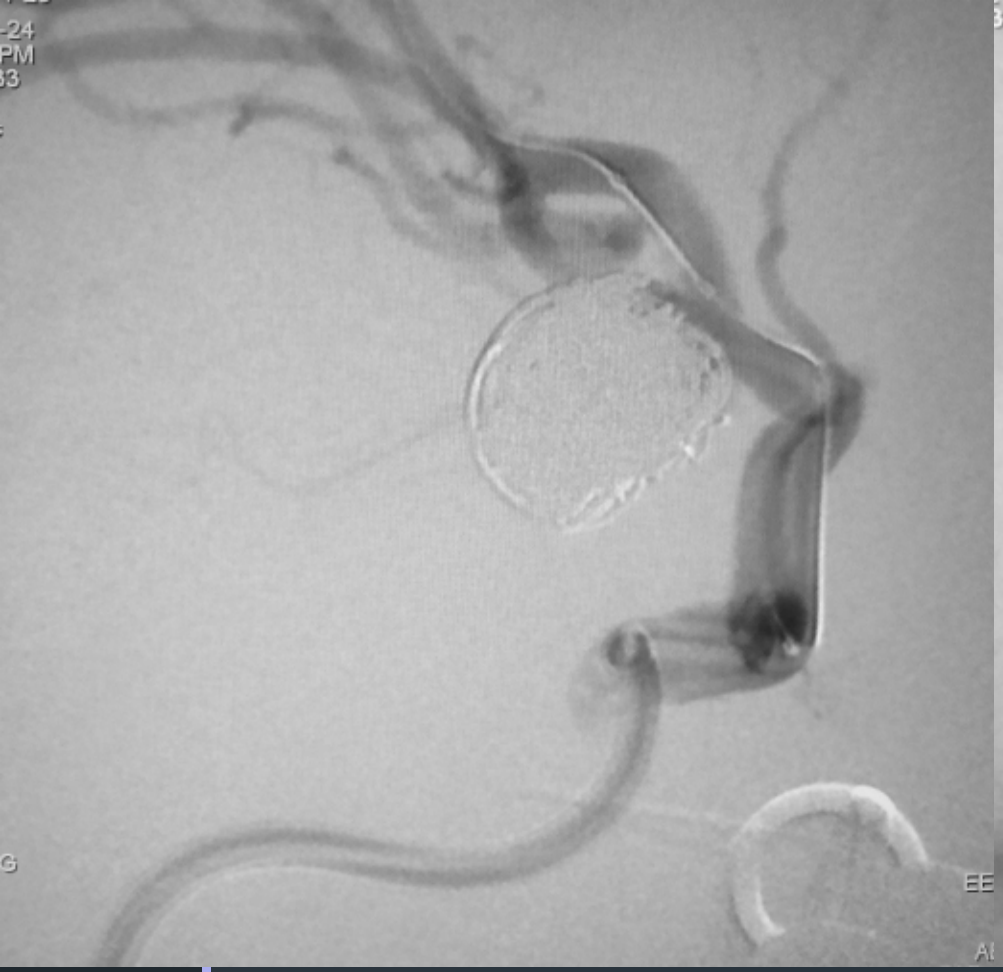

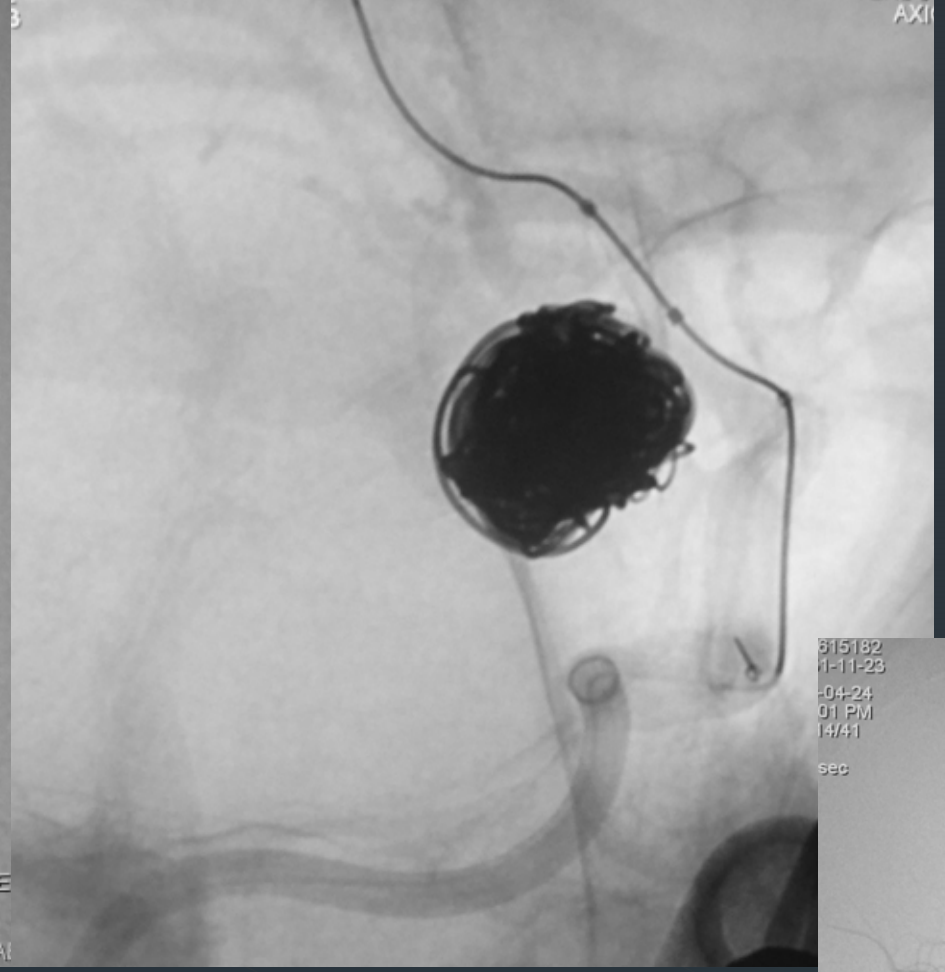

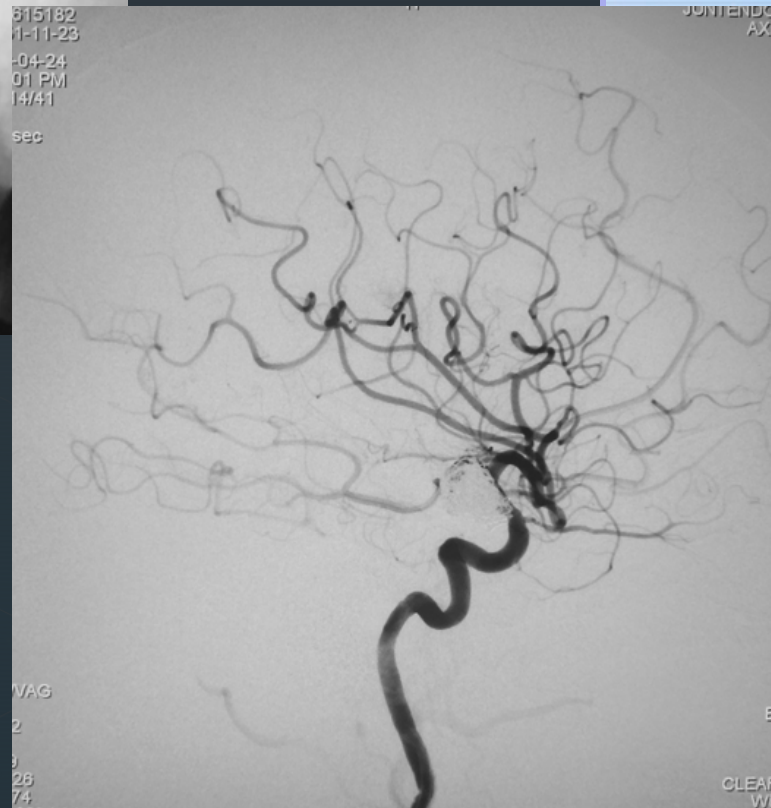

初回治療　balloon-assisted coiling

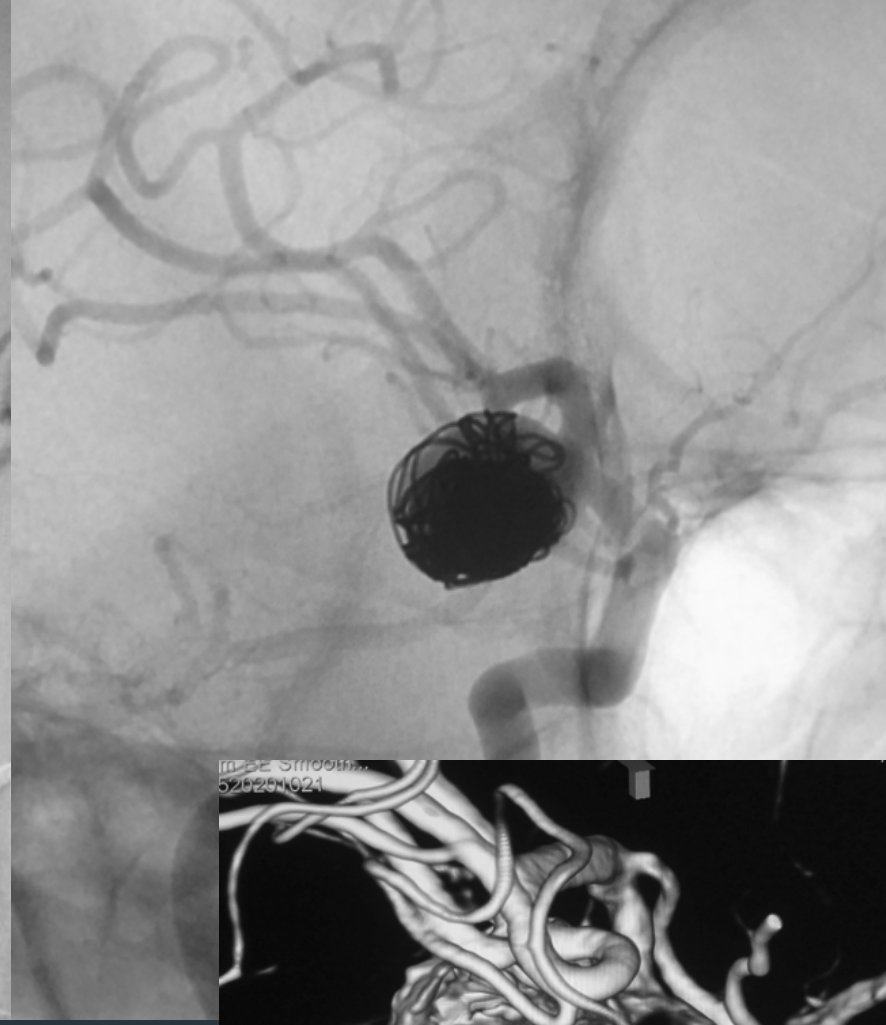

半年後再開通所見

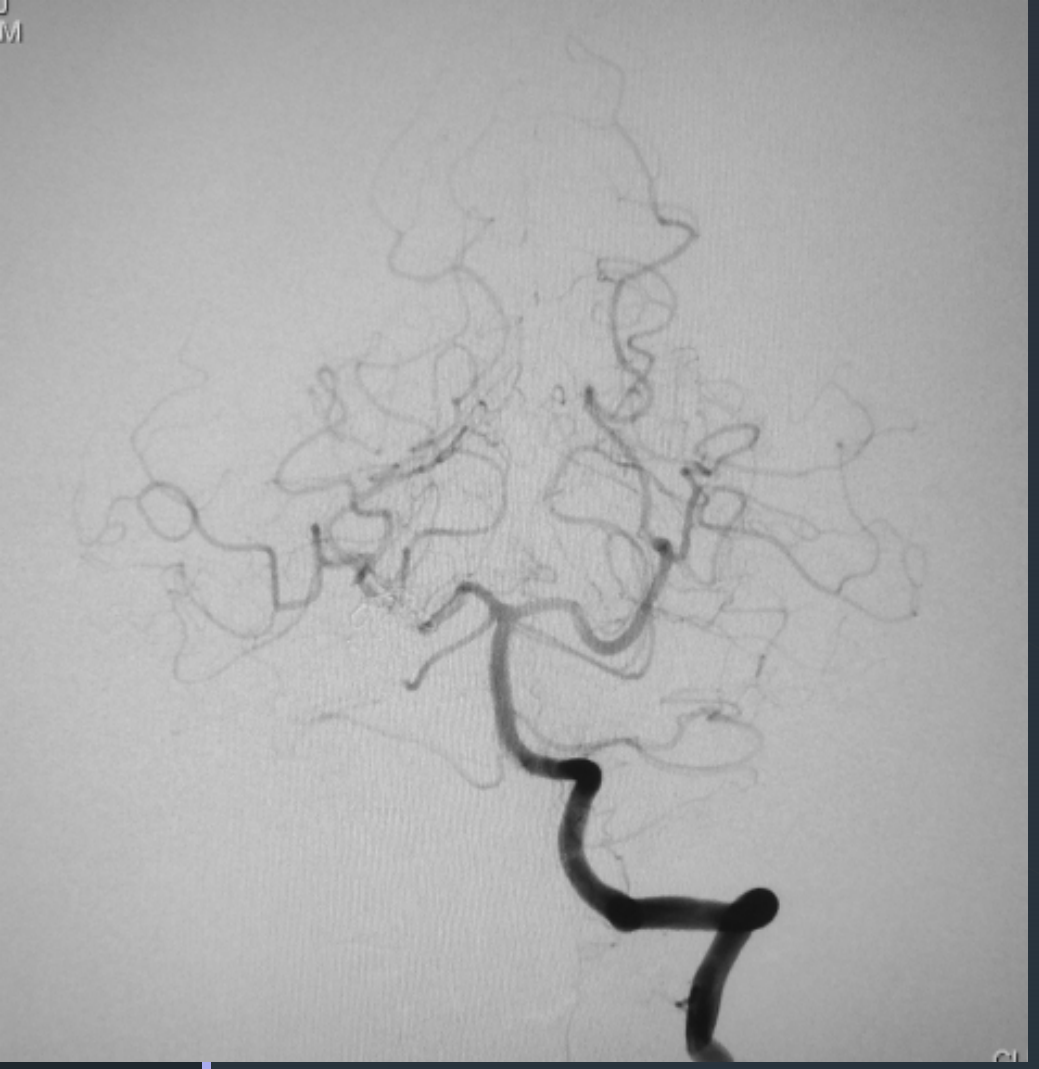

lt.VAG (alcock test)
→ Pcomは閉塞可能と判断