39歳男性　頭痛精査で発見されたAVM

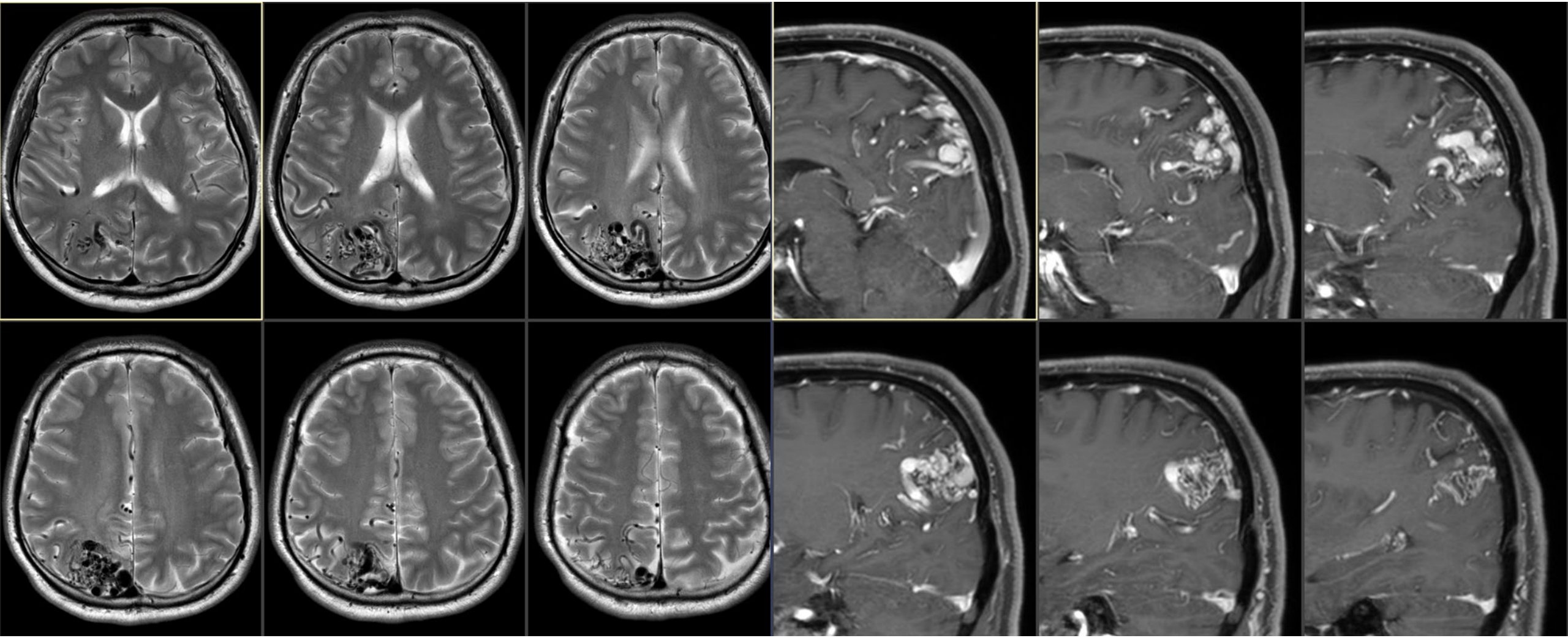

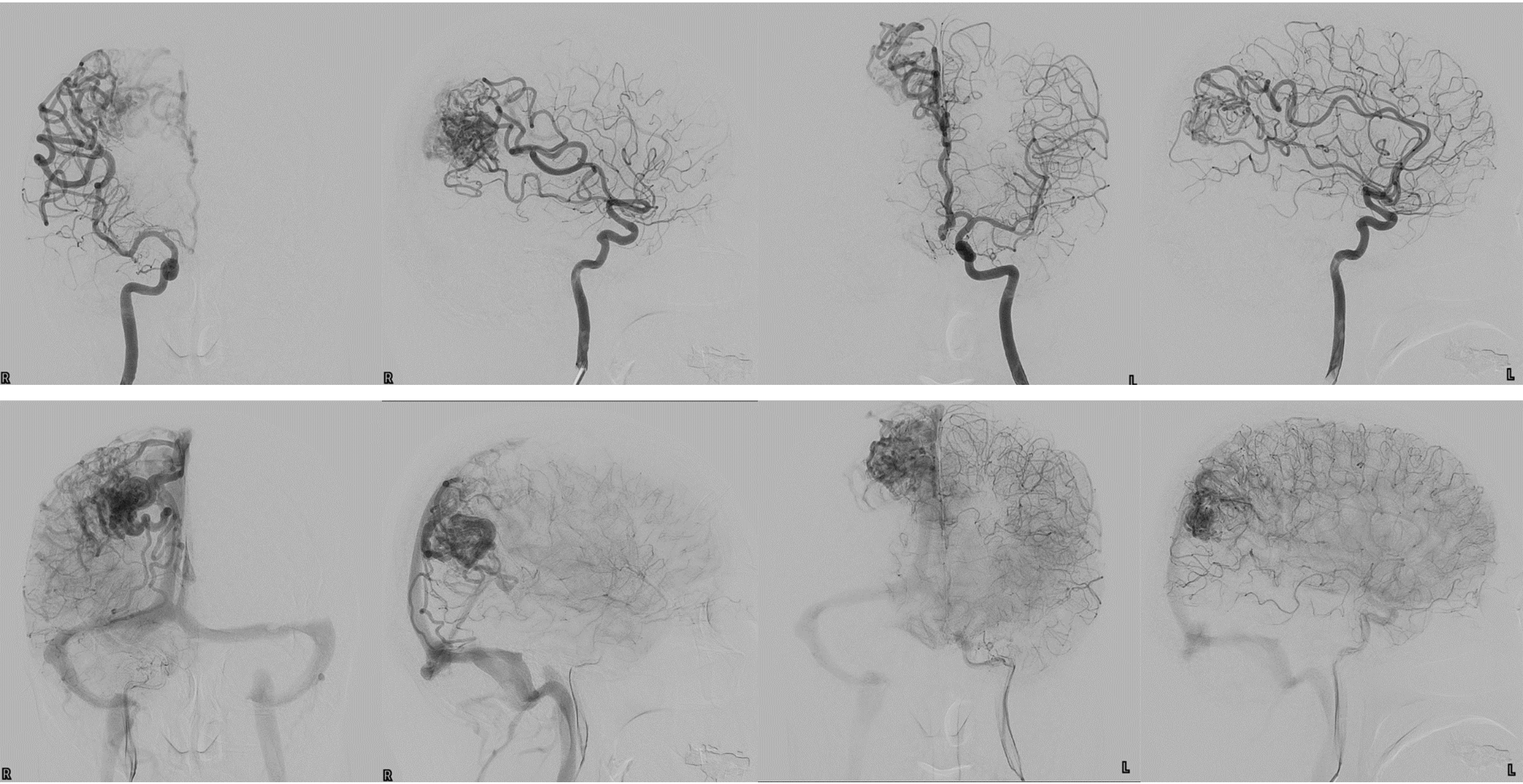
R
R
L
L
R
R
L
L

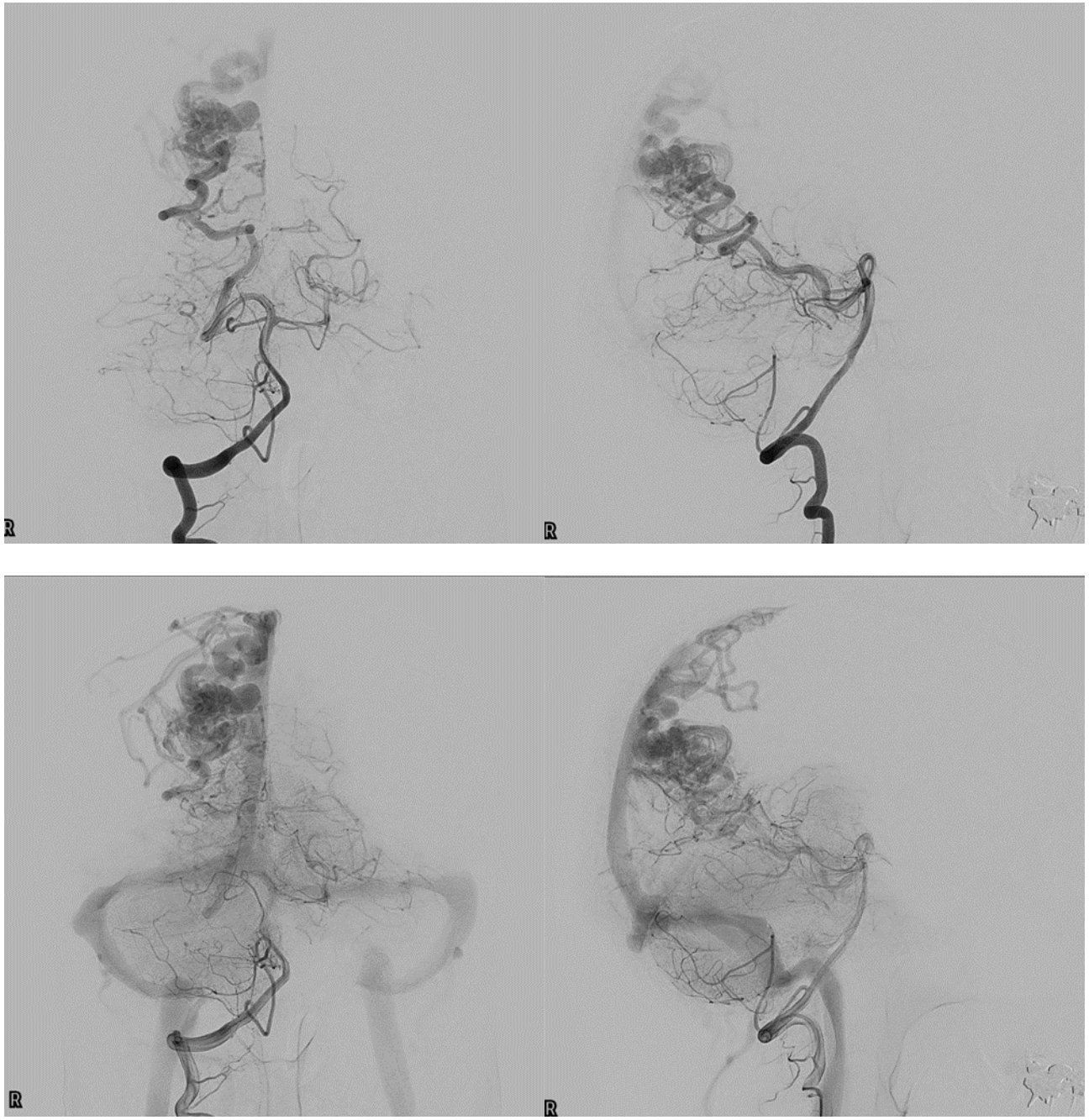
R
R
R
R

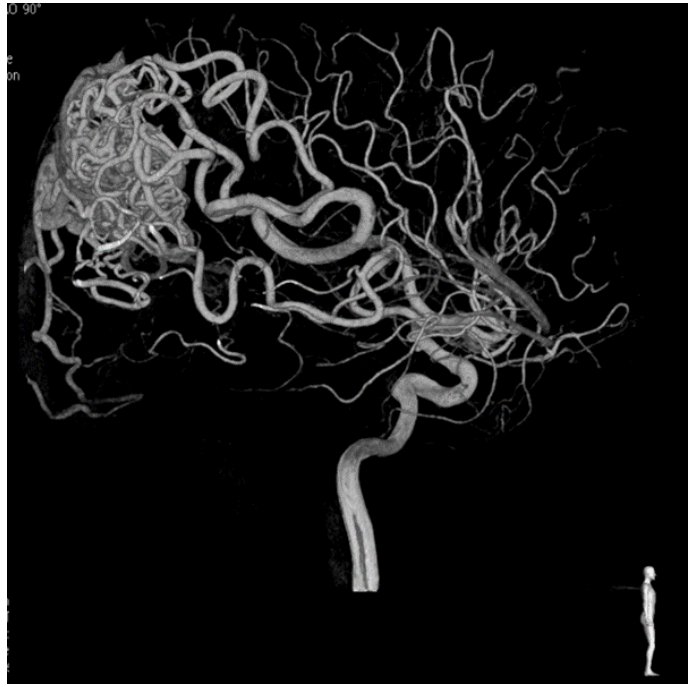

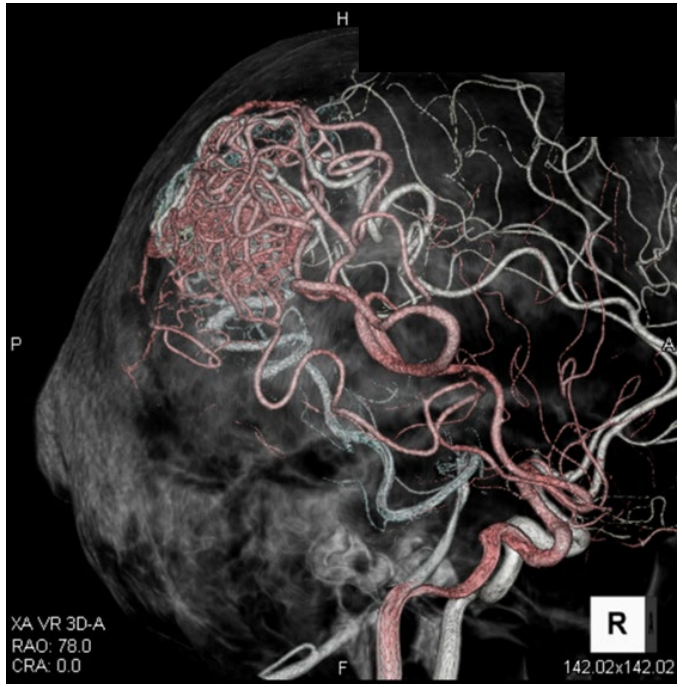
H
P
A
F
XA VR 3D-A
RAO: 78.0
CRA: 0.0
R
142.02x142.02

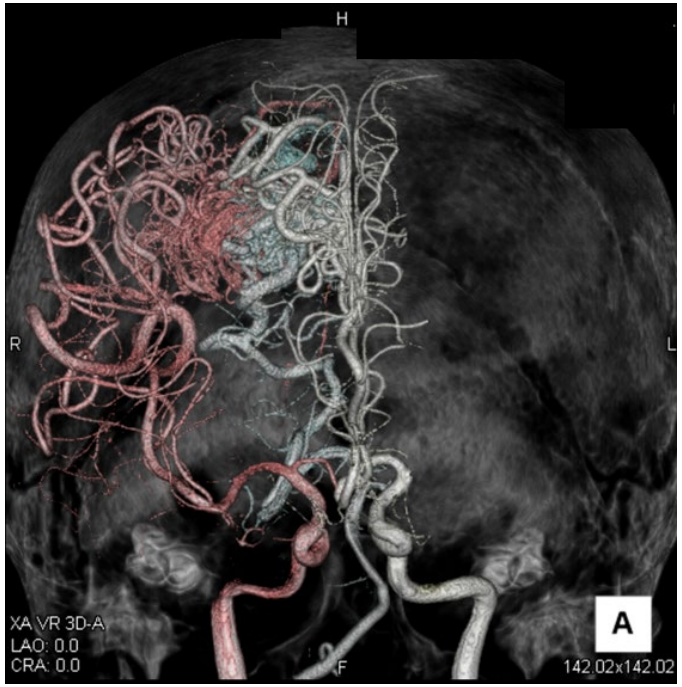
H
R
L
F
XA VR 3D-A
LAO: 0.0
CRA: 0.0
A
142.02x142.02

頭痛発症の若年性非出血脳動静脈奇形
右利き、神経学的所見なし
右頭頂葉を主座とするCompact nidus(大きさ46mm)

Feeder
ACA: Superior internal parietal artery, Inferior internal parietal artery
MCA: Anterior parietal artery, Posterior parietal artery, Angular artery, Temporo-occipital artery
PCA: Parieto-occipital artery
Drainer
Cortical vein(Anterior/Posterior parietal vein)→SSS
Internal occipital vein→Vein of Galen→Straight Sinus

Spetzler-Martin grade III (Size 2, non-eloquent, deep drainage)

多系統の血管からなる脳表AVM
深部からの穿通枝動脈は認めない
それぞれのfeederでcomponentが異なっている